

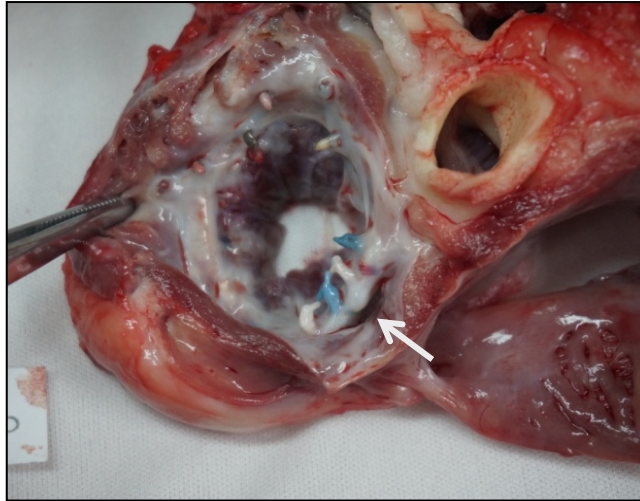Figure S1. A peri-leakage aside a manual-tying knot at Day 90 (↑).

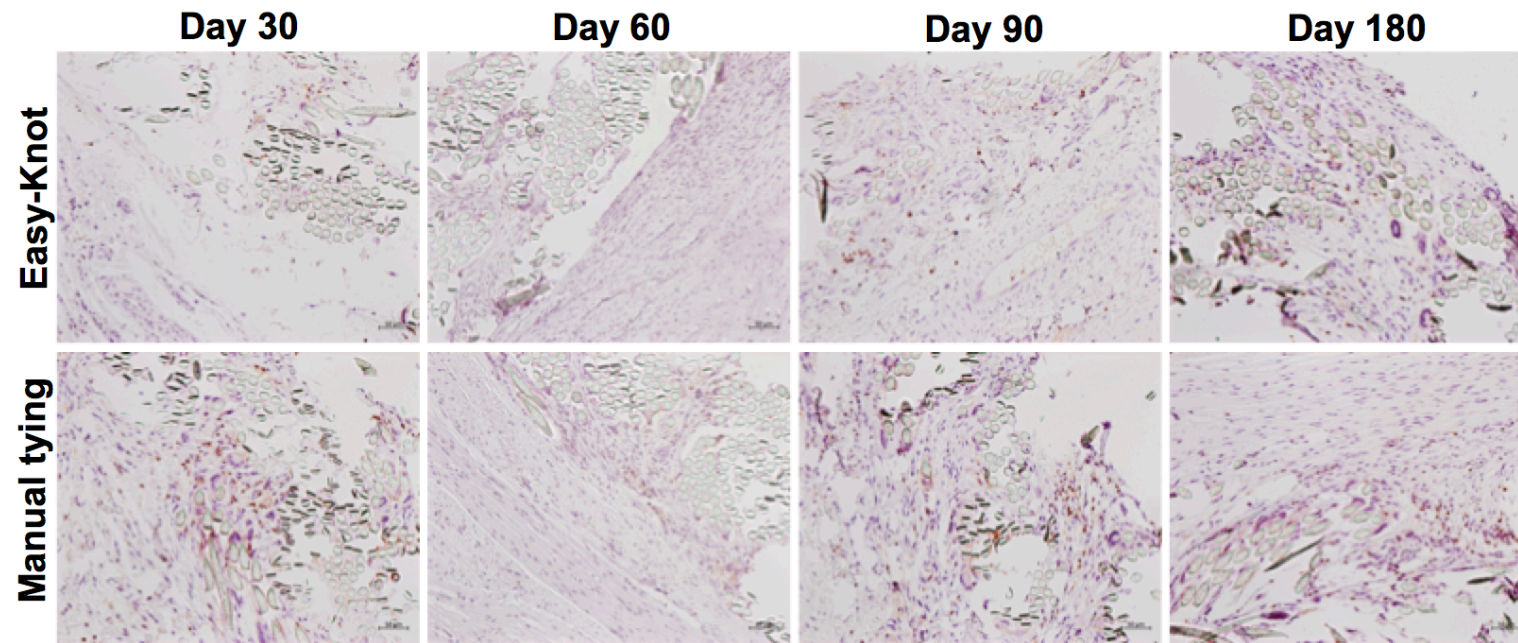


Figure S2. Representative IHC images of tissue around the annuloplasty ring at indicated time points for inflammatory reaction analysis. *, $P < 0.05$.